

# Back to Base

ICB Medical Newsletter

Issue 4

Telephone: +61 2 9545 4769

## Using Orthotics Made Easy: Plantar Fasciitis

By Abbie Najjarine  
BSc (Pod) - QMU UK  
Dip Pod - NSW



I am often asked by practitioners, "How do I know that my patient will benefit from orthotic therapy?"

From the outset we must understand that orthotics are not a 'cure-all'. Rather they are simply a tool for the practitioner to use in the treatment. Be assured however, that you can achieve great results when you combine ICB Orthotics within your modality.

During a patient's initial consultation they will generally outline a point of pain (P.O.P) and will be looking to gain quick, if not immediate relief. As practitioners we should be sensitive to the pain our patients suffer, however in my clinic I initially treat the P.O.P whilst at the same time endeavouring to identify the root cause which has triggered the symptomatic pain (in non trauma cases only).

Let's look at the case of a Plantar Fasciitis (heel spur syndrome) sufferer.

In this situation excessive Subtalar joint pronation lowers the arch structure causing the foot to elongate and traction forces are placed on the Plantar Fascia. This all results in inflammation of the plantar calcaneal attachments (Warren, 1990; Kibler et al, 1991).

The practitioner must first accurately identify where the pain is felt by the patient - medial heel pain, lateral heel

pain or central heel pain. The P.O.P is very important to identify as this will help determine the best form of treatment.

There are three aponeurosis under the foot - medial, centre and lateral attachments to the calcaneus. Thus it is critical to identify the point of pain, as it will greatly assist in the diagnostic process and subsequent treatment.

**Medial Heel Pain** - is associated with excessive pronation - more than the 4° the body allows. This causes the medial plantar fascia to elongate and tear away from the calcaneal attachment causing inflammation and pain.

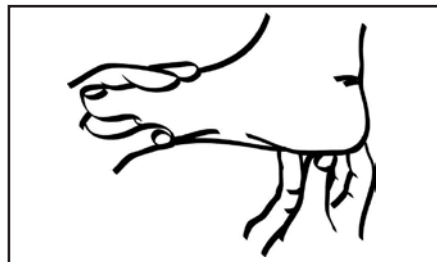


Fig. 1: Pain can be central, medial or lateral

**Central Heel Pain** - is associated with high lateral heel strike in gait to mid foot collapse, and pronation at mid stance of gait, together with a forefoot valgus deformity. When the foot lands laterally the ground, reaction forces propel the foot into pronation as it enters mid stance, causing middle or central plantar fascia tearing to occur, by creating a 'pivot point of tear effect'.

**Lateral Heel Pain** - is associated with a Pes Cavus foot structure or a high forefoot valgus which causes the lateral plantar fascia to strain from the

attachment. A fixed plantar flexed 1st ray can also cause lateral heel pain.

All the above will effect either lateral heel pain, medial heel pain or centre heel pain.

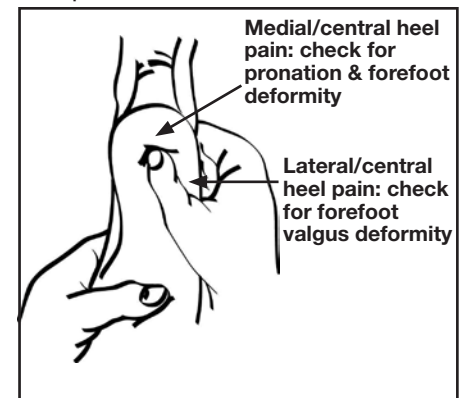


Fig. 2: Lateral heel pain

### Treatment

1. Check if the patient is pronating or supinating. Look at the amount of pronation by correcting the feet to neutral (Neutral Calcaneal Stance Position), then allowing the patient to relax (Resting Calcaneal Stance Position). This will identify the total pronation factor.

2. Check the patient's weight, so you will know which ICB Orthotic density will be most suitable, i.e. supporting the patients arch without collapsing under their body weight.

3. Identify if there is a forefoot valgus. If a forefoot deformity exists, attach the appropriate size forefoot addition to the orthotic prior to heat moulding. Then proceed to heat mould the orthotic, with the patients foot in the neutral calcaneal stance position.

4. When fitting orthotics always check if there is a structural leg length difference. If a leg length difference is detected the fitting of orthotics will

remedy any long leg compensation. If the patient has a short leg add a heel lift (i.e. 4mm) and build up gradually to the required height.

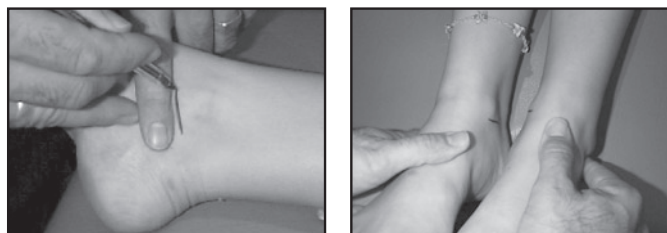


Fig. 3: Checking for a leg length difference using the NAS Technique.

5. Check the patient for a tight plantar fascia (See Figure 3 below) as this may cause orthotic compliance problems and irritation in the patients' arch.




Fig. 4: Check for tight plantar fascia.

If the patient does exhibit a tight plantar fascia, a plantar fascial groove will need to be made into the arch of the orthotic, after the heat moulding process. For more information on how to create a plantar fascial groove, go to: [www.icbmedical.com/modifying](http://www.icbmedical.com/modifying).

### Post-Compliance Issues

If after the wearing-in period the patient complains of pain under the arch caused by the orthotics, check the following:

1. Is the orthotic sufficiently controlling the pronation?
2. Is the patient's Neutral Calcaneal Stance Position

greater than the 5° built into the orthotics? If this is the case:

a. Check the density guide ([www.icbmedical.com/fitting](http://www.icbmedical.com/fitting)) and upgrade the patient to a more supportive controlling device, eg. change from an ICB Mid density Blue orthotic to a Firm Green orthotic.

b. If the density is correct but the device is not controlling the pronation, increase the inversion angle by adding a Rearfoot Varus Addition to the existing orthotic.

c. If the patient's NCSP measures higher than the 5° rearfoot varus angle built into each ICB Orthotic follow step b. and add the required Rearfoot Varus Addition and re-mould the orthotic.




Fig. 5: Adding a Rearfoot Varus Addition

### Additional Treatments

- Low Dye Strapping: to assist or mimic an orthotic
- R.I.C.E
- Foot Mobilisation
- Deep Tissue Massage - to break down fibrous tissue

### Differential Diagnosis

- Entrapment of the medial calcaneal branch of the tibial nerve.
- Tarsal Tunnel Syndrome

### References:

- KIBLER, W.B., GOLDBERG, C., & CHANDLER, T.J. (1991) *Functional Biomechanical Deficits in Running Athletes with Plantar Fasciitis*, the American Journal of Sports Medicine, 19, (1): 66-71
- MICHAUD, T.C. (1997) *Foot Orthoses and Other Forms of Conservative Foot Care*, Sydney: Williams & Wilkins
- WARREN, B.L (1990) *Plantar fasciitis in Runners: Treatment and Prevention*, Sports Medicine, 10 (5): 338-345