

# Back to Base

ICB Medical Newsletter

Issue 14

Telephone: +61 2 9545 4769

## Treating Back Pain & LLD using Orthotic Therapy

By Abbie Najjarine  
BSc (Pod) - QMU UK  
Dip Pod - NSW



Back pain is always interesting as there are so many causes of this problem. I want to keep it simple and address back pain and sacroiliac pain associated with leg length abnormality and how I treat the problem incorporating orthotics and other modalities.

Firstly leg length can be categorized into:

1. Structural – a difference in the long bone measurement of the leg and,
2. Functional - arising from a variety of causes which affect the biomechanics of the body.

When a patient presents with back pain I always start with the basics, and complete a full biomechanical assessment, which includes long bone measurement and a comparison of the amount of pronation/eversion and supination/ eversion at the foundation. The first thing to look for is whether the patient is presenting with bilateral or unilateral pronation. If it is UNILATERAL, I try to establish if the patient has:

- a. suffered a trauma in which one plantar fascia may have ruptured or elongated more so than the other, consequently, creating a functional short leg.
- b. tibial torsion with hip compensation: such as tight psoas which will rotate the pelvis anteriorly,

or tight piriformis ITB's and Gluteals, as a compensation for internal tibial torsion to correct the pigeon toed position. Both these compensations could either rotate the pelvis forward or backward creating functional leg length problems in the gait cycle.

If the patient has a long leg compensation in which the long leg drops down or pronates to level the pelvis, I then try to establish the true structural length and this can be verified using a CT scanogram (see Figure 1) for leg length or the normal

place a wedge to stop the rocking? Most will say YES! So if the rocking table annoys you, imagine how a leg length discrepancy of 3-4mm can upset the biomechanical structures.

If the patient is suffering from hip compensations they will need to be either referred to the appropriate Allied health practitioner to 'loosen-up' the pelvis and use stretching and strengthening exercises to correct the anomaly. At the same time prescribe orthotics to realign and correct the biomechanics. A combination of orthotic therapy and muscle stretching and strengthening will, in my experience, give the best treatment results.

If the patient presents with a structural deformity and it is not due to a recent trauma related imbalance, then the use of a heel raise on the structural short leg will be required. I recommend halving the leg length discrepancy measurement, and adding only that amount in the heel raise. Then this amount can be gradually increased, to limit initial discomfort and quicken patient compliance. Contraindication in this instance would be any fusing of the spine as this may cause the patient to be in more pain.

If you prescribe the patient orthotics and have NOT MEASURED leg length (when the patient does have a leg length discrepancy) the orthotic will invariably remove the normal body compensation of the 'long leg pronation'. This jamming action will create problems with the SI joint and the long leg may also contribute to the development of a scoliosis, as stated in Blake & Ferguson, 1992.

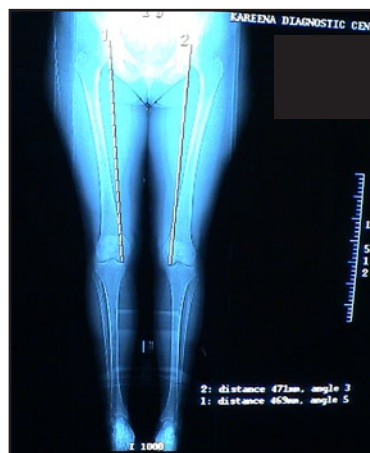

Figure 1: CT Scanogram

x-ray film to check the leg length.

The longer leg will be predisposed to hip joint wear and tear and may lead to the patient requiring a hip replacement in the future. Therefore if a patient is asymmetrical, inform them about the consequences of not treating the condition. Some practitioners say the body will take up and compensate for the difference and why bother with a heel raise to level the pelvis? However, suggest to them that if they were sitting at a table that rocks side to side, would they

Placing a heel lift in the shoe of the short leg without using orthotic devices is not recommended, as this will create a leg length problem on the raised leg side, because the longer structural leg will continue to pronate due to ligamental laxity as it has done over many years. The use of one orthotic is never recommended as the foundation needs to be balanced, and the necessary biomechanical corrective additions attached to the orthotic.

- Orthotics to treat 'long leg pronation', together with a heel raise being added for the short leg.
- Raise the short leg in stages - if the discrepancy is a large amount start with half the amount of measured discrepancy.
- Often a multi-disciplinary approach such as adjustments to 'free' the pelvis and check the head of femur is sitting correctly in the acetabulum, in combination with orthotic therapy, delivers the best results for the patient.

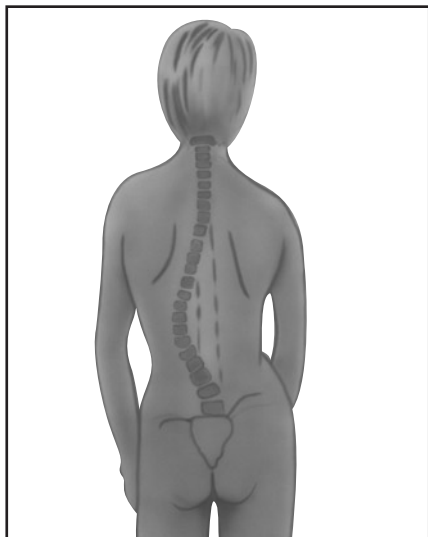


Figure 2: Scoliosis

Where back pain and SI joint pain is concerned I always recommend that leg length discrepancy is assessed and treated.

**Treatment**

- Measure and confirm structural or functional leg length discrepancy.




Figure 4: Orthotic with Forefoot Valgus addition.

**REFERENCES:**

Blake, R.L. and Ferguson H (1992) 'Limb Length Discrepancies' Merriman, LM and Tollafeld, DR (1995) 'Assessment of the Lower Limb'

Blake RL, Ferguson, H (1992) *Limb Length Discrepancies*. Journal of the American Podiatric Medical Association 1: 33-38.

Blustein SM, D'Amico JC (1985) *Limb Length Discrepancy - identification, Clinical Significance and Management*. Journal of the American Podiatric Medical Association 75(4): 200-206.