

# Back to Base

ICB Medical Newsletter

Issue 13

Telephone: +61 2 9545 4769

## Inversion Sprain, Lateral Pain, Forefoot Valgus Deformity and Orthotic Therapy

By Abbie Najjarine  
BSc (Pod) - QMU UK  
Dip Pod - NSW



I often read articles written on lateral sprain and pain associated with a pes cavus foot structure and a forefoot valgus deformity. In this article I will explain my views as to why I believe patients present with lateral sprain and strain and how to use a variety of treatment modalities, in combination with orthotic therapy, to treat the problem easily and successfully.

Often a patient will present with repetitive lateral ankle sprain or knee pain (or even lateral shin splints) and say that they have suffered with these problems for all of their life - or that upon commencing a new exercise regime problem has started to occur, and it is now impacting on their quality of life.

Because my patients would ask why this was happening to them, I needed to investigate and try to identify an underlying causation, as the pain should not be deemed 'idiopathic' and hence not addressed.

Pes cavus foot (high arch) structures (see Figure 1) are very interesting because it is given that they are a rigid structure and in nearly every case are a supinated foot structure. The patient will often indicate that their joints are painful and when they walk on floor boards at home without shoes they say, "You can hear me coming as I thump up and down the

hallway!"

Usually in this type of structure the patient will exhibit a forefoot valgus deformity which means that:

*The plantar plane of the forefoot remains everted relative to the plantar plane of the rearfoot when the subtalar joint is in neutral.*

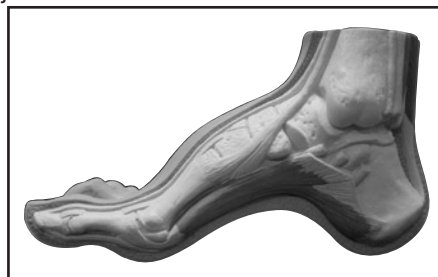


Figure 1: Pes Cavus Foot Structure

This deformity will have an impact on the patient in heel strike, midstance and toe off phase of gait. The patient who exhibits a pes cavus foot structure will usually present with a Forefoot valgus  $>10^\circ$  and will often exhibit a plantar flexed 1st metatarsal (Boyd & Bogdan, 1993), encouraging the foot to strike laterally and eliciting pressure on the lateral aspect of the hip joint.

If the Forefoot valgus deformity is  $>10^\circ$ , in my experience, the foot will continue to supinate through the cycle, having a jarring effect on the upper structure and will put additional strain on the Lateral aspect of the structure.

When the foot is supinated it causes extreme stress on the peroneals and may cause elongation of the muscles and tendons, thus weakening the retinaculum and lengthening the peroneals, causing the tendon to sublux off the lateral aspect of the malleolar.

The FFT Valgus (in gait) wants to reach the ground and propulsion is delayed causing lateral instability. As the foot strikes laterally it throws it into supination, resulting in tension and tearing on the peroneal muscles, causing inflammation and tenderness to touch, and difficulty walking.

Lateral ankle sprains are more common than medial due to the fact that ligaments are weaker on the lateral side. Hence the lack of lateral stability can be caused by uncompensated or partially compensated rearfoot, a flexible forefoot valgus or osseous forefoot valgus (Boyd & Bogdan, 1993; Hollis et al, 1995; Shapiro et al 1994).

There are also certain biomechanical foot deformities that make some patients more susceptible to inversion sprains such as neurological deficits and supinated foot types which exhibit or function with a supinated calcaneus (valmassy, 1996),

It is important to always assess patients that present with lateral

structural pain, for a forefoot valgus. When I assess I like to use the supine position rather than prone as it requires less movement of the patient on the bench and the patient can observe the assessment procedure thus they are actively involved in the explanation of the procedure. Assessing in the prone

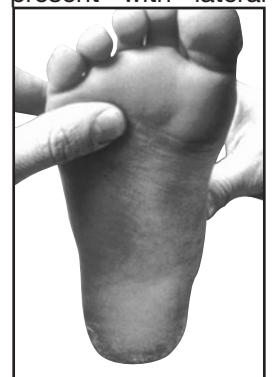


Figure 2a: Testing for a Forefoot Valgus.

Assessing in the prone

position is however ok, if you feel more comfortable doing so.

If the forefoot valgus is  $<10^\circ$  my observation is that the patient will supinate at heel strike, laterally rotate their foot to make ground contact and then pronate at mid stance to toe off (see Figure 3).

When the foot is supinated it causes extreme stress on the peroneals and may cause elongation of the muscles and tendons.

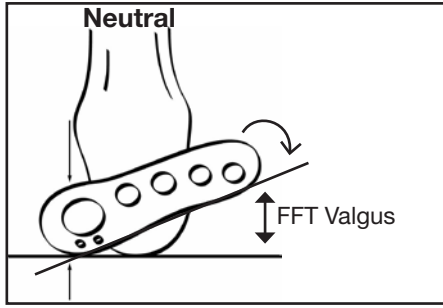


Figure 2b: Measuring FFT Valgus

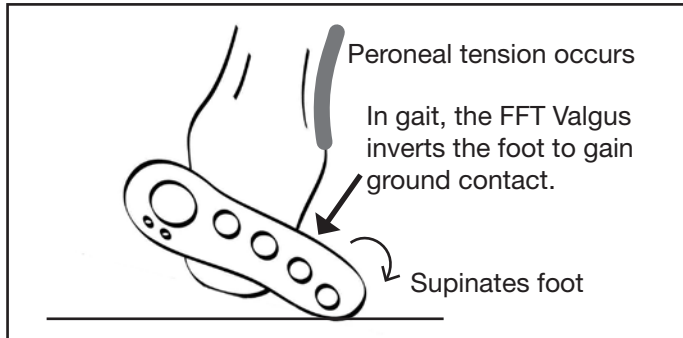


Figure 3: Forefoot Valgus during gait.

In summary, if a patient presents with lateral hip pain, knee pain, ankle strain or repetitive lateral inversion sprain, always check for a forefoot valgus deformity and employ the following treatment suggestions to assist in alleviating the painful symptoms, whilst most importantly treating the underlying causation.

If the patient requires a forefoot valgus posting to be added to their orthotic devices remember that the measured forefoot valgus deformity when applied should be reduced by the amount of rearfoot varus correction when the foot is corrected to neutral.

**Formula: FFT Valgus (measured as a -ve) + NCSP (measured as a +ve) = Resultant Valgus addition.**

For example if the rearfoot measures  $+4^\circ$ , plus the assessed forefoot measurement of  $8^\circ$  = resultant valgus addition of  $-4^\circ$ . If this step is excluded and the full valgus

is applied, the patient will feel that the addition is too much and the metatarsal shafts will feel that they are jamming, which may encourage pronation in midstance to toe off.

If the forefoot valgus is very large say  $>15^\circ$ , a lower amount may need to be applied to assist the patient in being able to get the orthotic into the shoe.

#### Suggested Treatment Options for Lateral Pain:

- Deep tissue massage along the peroneal muscles or suction cups to break down scarring and adhesion.
- Orthotic device with an appropriately sized forefoot valgus addition applied (see Figure 4). Always start with a conservative sized valgus addition, and build up from there to assist compliance.
- Acupuncture at the point of pain.
- Lateral Prolotherapy to strengthen the lateral ankle ligaments to encourage proliferation of the lateral ligaments (formation of collagen fibres).
- Mobilisation of the cuboid joint, as this may become subluxed.
- For lateral ankle sprains use stabilising ankle strapping, in combination with the orthotic device.




Figure 4: Orthotic with Forefoot Valgus addition.

#### REFERENCES:

- BOYD, P.M. & BOGDAN, R.J. 1993. Sports Injuries. In LORIMER, D.L. Neales Common Foot Disorders: Diagnosis & Management: A General Clinical Guide (4th Ed). Churchill Livingstone, Edinburgh, P. 179-180
- HOLLIS, J.M., BLASIER, R.D., CHARELENE, M.F. & HOFMANN, O.E. 1995. *Biomechanical Comparison of Reconstruction Techniques in stimulated lateral Ankle Ligament Injury*. The American Journal of Sports Medicine, 23, (6), p.678-682
- SHAPIRO, M.S., KABO, J.M., MITCHELL, P.W. & LOREN, G. 1994. *Ankle Sprain Prophylaxis: An Analysis of the Stabilising Effect of Braces and Tape*. The American Journal of Sports Medicine, 22, (1), p 78-82.
- VALMASSY, R.L.. *Pathomechanics of Lower Extremity Function*. In VALMASSY, R.L. Clinical Biomechanics of the Lower Extremity. Mosby, St Louis. p 75